

Anesthetic Considerations in Takayasu's Arteritis — A Case Report

Po-Kai Wang, Bo-Han Luo, Albert Chen, Yi Lee, Hsien-Yong Lai

Department of Anesthesiology, Buddhist Tzu Chi General Hospital and Tzu Chi University, Hualien, Taiwan

ABSTRACT

Takayasu's arteritis (TA) is a rare, chronic progressive panendarteritis involving the aorta and its main branches. Anesthesia for patients with TA is complicated by their severe uncontrolled hypertension, end-organ dysfunction, stenosis of major blood vessels, and difficulties encountered in monitoring arterial blood pressure. We present a 47-year-old woman with TA with both subclavian and femoral artery stenosis. This patient received two artificial vascular grafting operations, the first under general anesthesia and the second under epidural anesthesia. Unfortunately, she died at the end of the second operation due to a sudden onset of bradycardia and hypotension. We review reports about anesthetic considerations in TA and discuss the possible reasons for failure to resuscitate the patient. (*Tzu Chi Med J* 2006; **18**:53-56)

Key words: Takayasu's arteritis, epidural anesthesia, bradycardia

INTRODUCTION

Takayasu described a rare illness characterized by occlusion of the principal arteries arising from the aortic arch. This disease is also referred to by many other names, including pulseless disease, aortic arch syndrome, young female arteritis, idiopathic aortitis, reversed coarctation, and Martorell syndrome [1,2]. It affects females in over 85% of cases. The major clinical finding is loss of palpable pulses in the upper limbs and neck. The unsuspected ischemia in vital regional vascular beds may be associated with high anesthetic risks for these patients. This case report discusses the anesthetic management of a patient with this condition with special reference to intraoperative monitoring techniques.

CASE REPORT

A 47-year-old woman was scheduled to receive

bypass grafting surgery due to severe left subclavian and left femoral artery stenosis. She also complained of visual disturbance and presyncope. Due to the multiple arteries involved, Takayasu's arteritis (TA) was diagnosed.

Preoperative physical examination showed that the carotid pulse was decreased on the left side. Left upper limb and left lower limb pulses were almost impalpable. Korotkoff sounds were audible in the brachial artery of the right upper limb where the blood pressure was 178/98 mmHg. The remainder of the physical examination was normal. Hematocrit, hemoglobin, and serum chemistries, as well as the electrocardiogram (EKG) and chest roentgenogram (CXR) were all within normal limits.

Aortography revealed total occlusion of left subclavian artery (Fig. 1) and 85% stenosis of the left common iliac artery. The right common carotid artery was patent and the left common carotid artery had 50% stenosis. The retinal arteries were irregular with partial stenosis. There was no evidence of other lesions, in ei-

Received: August 26, 2005, Revised: September 20, 2005, Accepted: November 1, 2005

Address reprint requests and correspondence to: Dr. Hsien-Yong Lai, Department of Anesthesiology, Buddhist Tzu Chi General Hospital, 707, Section 3, Chung Yang Road, Hualien, Taiwan

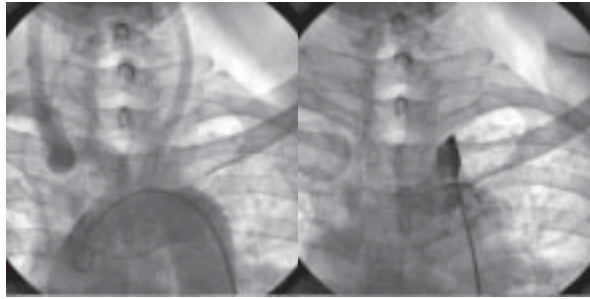


Fig. 1. Aortogram and selective angiogram of this patient: (A) Aortogram of the arch vessels. The left subclavian artery is not visible. (B) Selective angiogram with the catheter tip in the proximal portion of the left subclavian artery, revealing total obstruction.

ther the renal or pulmonary arteries.

General anesthesia was induced with intravenous (IV) thiopental 2 mg/kg and the trachea was intubated following rocuronium administration. Anesthesia was maintained with 3% sevoflurane in oxygen, while rocuronium and fentanyl were added as needed. Intraoperative monitoring included ECG, pulse oximetry, body temperature, capnography and central venous pressure (CVP). The right radial artery was selected for direct arterial pressure monitoring because it had a strong pulse and was easily accessible. The intraoperative period was uneventful. Rocuronium was reversed with neostigmine prior to extubation. The recovery period and postoperative course were unremarkable.

Two months later, she was scheduled for artificial vascular grafting due to occlusion of the left femoral arterial graft. This time we selected epidural anesthesia because the operation was limited to the lower extremities. Due to the patient's request, light intravenous sedation with a propofol infusion was given. Epidural anesthesia was performed with 3 mL of 2% lidocaine administered as a test dose with another 10 mL given 5 minutes later. A total dose of 13 mL of 2% lidocaine was given via an epidural catheter with entry at the L3-4 interspace. The sensory blockade level was T6 by pinprick skin test. Intraoperative monitoring devices were identical to those for the previous operation. Anesthesia was maintained with 2% lidocaine as needed (total dose: 43 mL) and continuous intravenous propofol was infused at a rate of 150 mg/hour for sedation. Pure oxygen via face mask was applied at a flow rate of 6 L/min during the whole operative period and the pulse oximeter revealed a SpO₂ of 100%. During the initial operative period the arterial blood gas data and electrolyte profiles were all within normal limits (pH: 7.401, PaO₂: 254 mmHg, PaCO₂: 36.3 mmHg, BE: -1.1

mEq/L, Na⁺: 141 mEq/L, K⁺: 3.0 mEq/L, Cl⁻: 102 mEq/L, Ca⁺⁺: 0.97 mEq/L, sugar: 137 mg/dL, Hb: 13.1 g/dL, Hct: 39%) and vital signs were stable (preoperative BP: 170/105 mmHg, HR: 73 beat/min; after induction BP: 110/70 mmHg, HR: 82 beat/min; during surgery BP: 120/84 mmHg, HR: 84 beat/min). After about 2 hours of surgery, the total blood loss was about 1800 mL and the volume of intravenous crystalloids given was 2000 mL. Four units of whole blood were transfused and the CVP readings were kept around 8 mmHg, similar to the preoperative readings. The operation seemed to proceed uneventfully after blood transfusion and no further bleeding was noted. The propofol infusion was stopped 10 minutes before skin closure with a total dose of about 500 mg. The total operative time was about 4 hours. At the end of skin closure, a sudden onset of bradycardia (heart rate decreased from 75 beat/min to 50 beat/min) combined with hypotension (BP decreased from 120/85 mmHg to 70/50 mmHg) was noted. Intravenous atropine 0.5 mg and ephedrine 8 mg were administered, but the heart rate decreased further. The cardiovascular surgeon reopened the operative wound to check for bleeding, but no further bleeding was noted. Another dose of atropine 1 mg and ephedrine 16 mg were given with no results. Cardiopulmonary resuscitation was started with tracheal intubation, intravenous injection of epinephrine and intravenous fluid challenge. Arterial blood gases and electrolyte data revealed no abnormal findings (pH: 7.317, PaCO₂: 48.3 mmHg, PaO₂: 205.6 mmHg, HCO₃⁻: 24.8 mEq, BE: -0.9, Na⁺: 141 mEq, K⁺: 3.1 mEq, Ca⁺⁺: 1.07 mEq, Hct: 31%, sugar: 143 mg/dL). The pulse oximeter also revealed good waveforms and the SpO₂ remained at 100%. Despite the administration of large doses of catecholamines (40 mg of epinephrine), the heart still showed no response and finally stopped. Cardiac massage and direct current (DC) shock were applied with no response. The patient died after 45 minutes of resuscitation.

DISCUSSION

TA is characterized by a focal stenosis process involving the aorta and the proximal segments of its main branches [1]. It results in narrowing of the arterial lumen with a consequent distal ischemia and loss of pulse distal to the site of the lesion; hence the term 'pulseless disease'. Four types of TA can be distinguished [2]. Type I disease involves the aortic arch and its main branches, type II lesions are restricted to descending thoracic and abdominal aorta, type III shows features of both type I and type II, and type IV also involves the pulmonary

artery. Our patient presented with type III TA with involvement of the subclavian and femoral arteries.

In previous reports, great emphasis has been placed on the importance of hemodynamic monitoring in these patients [3]. Obtaining reliable blood pressures was not a problem in this patient since she had good pulses in her right arm. Some authors have advocated the insertion of a pulmonary artery catheter in selected patients [4]. But in the present case, there was no indication that warranted the use of a pulmonary artery catheter, since the chest radiograph was normal and there were no symptoms of pulmonary hypertension.

Blood pressure control is of paramount importance since patients with TA can have arterial aneurysms and cerebral dysfunction from carotid occlusion. The use of epidural anesthesia results in a lower rate of thrombosis and re-occlusion of grafts than general anesthesia, and it has an advantage over regional anesthesia because sympathetic block-induced hypotension can be avoided.

Although epidural anesthesia combined with a light general anesthetic has had widespread application [5], at least 15 mL/kg of crystalloid should be given before initiation of epidural block. In addition, the administration of local anesthetic should be very slow, allowing time to adjust for the development of sympathetic blockade. In this patient with carotid stenosis and a history of syncope, caution was needed with intravenous propofol sedation because it may mask neurologic signs and make it difficult to detect cerebrovascular insufficiency. Since patients with TA have poor cardiac function, cardiovascular drugs are often necessary for management. Although the use of a flow-directed pulmonary artery catheter has been recommended, we think that CVP measurement provided adequate information about cardiac preload in this patient.

The sudden onset of bradycardia and hypotension in the second operation may have been a combined result of blood loss and high sympathetic blockade with intravenous propofol sedation. However, cerebrovascular insufficiency, myocardial ischemia or cerebral embolism may have contributed to her postoperative complications. Cerebrovascular insufficiency after propofol sedation may explain the sudden onset of bradycardia and hypotension. Although the CVP value was normal during the operation, this does not insure that there was adequate blood flow to the brain, especially since this patient had a history of syncope and carotid artery stenosis. The subsequent failure of resuscitation may be due to poor myocardial performance and low cerebrovascular perfusion pressure.

If general anesthesia or intravenous sedation is used, neurologic monitoring is recommended if the patient has

a history of syncope and carotid artery stenosis. The use of a computerized electroencephalography monitor during anesthesia allows continuous assessment of the adequacy of cerebral flow [6].

In conclusion, though the exact reasons for the sudden onset of bradycardia and hypotension in this patient were not known, inadequate cerebral perfusion, myocardial ischemia or infarction and cerebral vascular embolism should be all considered. Anesthetic technique is only one factor affecting patient outcome after peripheral vascular surgery [7]. Even with good anesthetic care (i.e. no routine pulmonary artery catheterization or prolonged intensive monitoring), patients having peripheral vascular surgery experience a relatively high rate of complications. Any technique that reduces the complication rate should be implemented, including adequate administration of crystalloid, treatment of hypotension with fluid, Trendelenburg position, and IV ephedrine [8]. We describe two anesthetic methods for a patient with TA. Epidural anesthesia should be used cautiously in a patient with TA and poor cardiac and cerebral function. The use of neurologic monitoring in a patient with TA receiving general anesthesia or epidural anesthesia with sedation is also very important [9]. In patients with carotid artery involvement, general anesthesia or intravenous sedation should be performed under neurologic monitoring to prevent cerebrovascular insufficiency.

REFERENCES

1. Lupi-Herrera E, Sanchez-Torres G, Marcushamer J, Mispireta J, Horwitz S, vela JE: Takayasu's arteritis. Clinical study of 107 cases. *Am Heart J* 1977; **93**:94-103.
2. Ishikawa K: Natural history and classification of occlusive thromboaropathy (Takayasu's disease). *Circulation* 1978; **57**:27-35.
3. Thorburn JR, James MF: Anesthetic management of Takayasu's arteritis. *Anesthesia* 1986; **41**:734-738.
4. Winn HN, Setaro JF, Mazor M, Reece EA, Black HR, Hobbins JC: Severe Takayasu's arteritis in pregnancy: The role of central hemodynamic monitoring. *Am J Obstet Gynecol* 1998; **159**:1135-1136.
5. Beilin Y, Bernstein H: Successful epidural anaesthesia for a patient with Takayasu's arteritis presenting for caesarean section. *Can J Anaesth* 1993; **40**:64-66.
6. Kawaguchi M, Obsumi T, Nakajima T, Kuro M: Intraoperative monitoring of cerebral haemodynamics in patients with Takayasu's arteritis. *Anaesthesia* 1993; **48**:496-498.
7. Warner MA, Hughes DR, Messick JM: Anesthetic management of a patient with pulseless disease. *Anesth Analg* 1983; **62**:532-535.

8. McKay RS, Dillard SR: Management of epidural anesthesia in a patient with Takayasu's disease. *Anesth Analg* 1992; **74**:297-299.
9. Subramanian K, Shivanand C, Virender KA, et al: Anesthetic management of patients with Takayasu's arteritis: A case series and review. *Anesth Analg* 2001; **93**:60-65.